



## Stimulation of Quiescent and Mildly Infected Diabetic Foot and Venous Ulcers using a Wound Optimizing Irrigant

Journal:	<i>International Wound Journal</i>
Manuscript ID	Draft
Wiley-Manuscript type:	Original Article
Keywords:	biofilm, chronic wound, diabetic foot ulcer, SilverStream, venous leg ulcer, wound irrigant
Abstract:	<p>This study represents the first observational analysis for the treatment of mildly infected, non-progressive diabetic foot ulcers and venous leg ulcers treated with SilverStream<sup>®</sup>, a wound irrigant used to stimulate healing by reducing bacteria count, disrupting biofilms, eliminating odor, and stimulating angiogenesis.</p> <p>Data collected from 39 wounds at 8 independent sites was reviewed to determine the change in overall appearance and conditions following either daily or weekly treatment with SilverStream over a period of 5 weeks.</p> <p>The wounds demonstrated significant decreases in discharge, odor and necrotic or non-viable tissue. 21.5% of the wounds closed completely in 5 weeks or less, and the average decrease in wound size was 59.08% in wounds that were initially between 1 and 15 cm<sup>2</sup>. There was a 19% increase in granulation tissue and a 9% decrease in fibrotic and non-viable tissue during the same 5 week period.</p> <p>This preliminary data strongly suggests that quiescent wounds can be stimulated to begin healing with this wound irrigant. SilverStream fills a unique niche in the treatment of diabetic foot ulcers and venous leg ulcers by optimizing conditions necessary for these wounds to close.</p>

SCHOLARONET<sup>™</sup>

Manuscripts

Submitted for publication to the International Wound Journal

TITLE PAGE

**Stimulation of Quiescent and Mildly Infected Diabetic  
Foot and Venous Ulcers using a Wound Optimizing Irrigant**

Adam Landsman, DPM, PhD, FACFAS

Chief, Division of Podiatric Surgery, Cambridge Health Alliance

Assistant Professor of Surgery, Harvard Medical School

1493 Cambridge St., Cambridge, MA 02139

OFFICE: 617-665-2555

FAX: 617-665-3511

[alandsman@cha.harvard.edu](mailto:alandsman@cha.harvard.edu)

*All correspondence and requests for reprint should be sent to this author.*

ABSTRACT:

This study represents the first observational analysis for the treatment of mildly infected, non-progressive diabetic foot ulcers and venous leg ulcers treated with SilverStream<sup>®</sup>, a wound irrigant used to stimulate healing by reducing bacteria count, disrupting biofilms, eliminating odor, and stimulating angiogenesis.

Data collected from 39 wounds at 8 independent sites was reviewed to determine the change in overall appearance and conditions following either daily or weekly treatment with SilverStream over a period of 5 weeks.

The wounds demonstrated significant decreases in discharge, odor and necrotic or non-viable tissue. 21.5% of the wounds closed completely in 5 weeks or less, and the average decrease in wound size was 59.08% in wounds that were initially between 1 and 15 cm<sup>2</sup>. There was a 19% increase in granulation tissue and a 9% decrease in fibrotic and non-viable tissue during the same 5 week period.

This preliminary data strongly suggests that quiescent wounds can be stimulated to begin healing with this wound irrigant. SilverStream fills a unique niche in the treatment of diabetic foot ulcers and venous leg ulcers by optimizing conditions necessary for these wounds to close.

KEY POINTS:

1. SilverStream is a wound management solution that has been shown to be effective in reducing odor and fibrous tissue while stimulating the formation of granulation tissue.
2. There is a significant role for SilverStream to be used to prepare a wound for future treatments such as skin grafts or treatment with advanced biologics.

3. This study illustrates that wounds treated with SilverStream appear to be healthier and this can be attributed to the disruption of biofilms, reduction of bacterial count, and stimulation of granulation tissue formation.

KEY WORDS:

biofilm, chronic wound, diabetic foot ulcer, SilverStream, venous leg ulcer, wound irrigant

Submitted for Publication

INTRODUCTION:

Quiescent wounds have been described in various terms but are typically characterized as wounds with elevated amounts of slough, biofilms, and increased bacterial count. These wounds have a chronic absence of new granulation tissue and rarely change in size for periods of a month or more. They have also been noted to exhibit excessive serous drainage and odor. Historically, these non-productive wounds have been treated with advanced biologics as well as topical and oral antibiotics. Their lack of progression is often misinterpreted as microvascular disease, or possibly even nutritional deficiencies. Although in some cases these assumptions may be correct, there frequently remains little improvement after these issues have been addressed.

The study by Sheehan, et. al. was one of the first to address the idea that quiescent wounds will typically remain quiescent unless some significant change occurs to the environment of the wound<sup>(1)</sup>. According to this study, those patients who had a wound that closed by at least 53% during the first 4 weeks of treatment had a 58% chance of closure by week 12. Conversely, those wounds that do not show a significant reduction in size during the first 4 weeks of treatment have only a 9% chance of closure by week 12. Thus, it is critical that when a wound becomes quiescent, the clinician must take action in order to stimulate healing. Furthermore, there should be measurable improvement in a relatively short period of time following initiation of the new regiment.

The purpose of the current analysis is to examine the response of these chronic wounds to a combination of materials designed to gently debride the wound while disrupting biofilms and reducing bacterial load. Various parameters were monitored to determine how many of those characteristics associated with chronic wounds would change after treatment.

SilverStream<sup>®</sup> is a new wound management solution specifically formulated to optimize conditions in difficult wounds. The primary ingredient of SilverStream, ionic silver, is used to reduce bacterial load<sup>(2,3)</sup>. In a study conducted at the Center for Biofilm Engineering at Montana State University, SilverStream was shown to disrupt biofilms and reduce bacteria viability. In this study, there was approximately a Log 3 reduction in CFU/cm<sup>2</sup> in both *Staphylococcus aureus* and *Pseudomonas aeruginosa* concentrations after only 10 minutes of contact and Log 5 reduction after 55 minutes of contact, essentially resulting in total destruction of the biofilm. In comparison, normal saline resulted in approximately Log 1 reduction after 6 hours of contact (FIGURE 1)<sup>(4)</sup>. The solution also contains menthol which has been shown to potentiate the effect of silver by retaining the anti-bacterial action at a lower, safer silver concentration. The potentiation of silver with a menthol additive is based on proprietary information from internal studies conducted by EnzySurge, Ltd. The menthol component leads to deeper penetration of the solution, and this enhances changes beneath the wound surface resulting in even greater reduction in bacterial contamination exudate. Menthol enhances cellular migration as well as penetration of the silver solution into the wound bed and helps to dry up wound exudate while giving the patient a soothing sensation during treatment.

Glycerol is a hypertonic aqueous solution that is also found in SilverStream and helps to reduce the potential for maceration of the wound while trapping and removing exudates and microorganisms. Normally, maceration is especially problematic in the chronic exudative wound because it separates the tissue planes and allows for deeper contamination of the wound bed. By reducing maceration and trapping debris, SilverStream helps to condition the wound. Tris Buffer is also present, and helps to maintain a neutral pH, further protecting the host cells.

Wound debridement is achieved by mechanically dislodging debris through the use of Tween 20, a surfactant and detergent that binds and removes necrotic debris from the wound surface.

The combination of reduced maceration, enhanced cellular migration, removal of debris and the reduction in bacterial load through the disruption of biofilm formation results in an overall optimization of the wound environment. Preliminary data has demonstrated that this sets the stage for the non-progressive wounds to begin the healing process. Once conditions have been optimized, the wound will shift from a quiescent, protective state to one characterized by progression of healing.

SilverStream, created by EnzySurge, Ltd., Israel, was cleared by the FDA in 2009 for the treatment of diabetic foot ulcers, venous leg ulcers, and other types of difficult, non-progressive wounds. This study represents data from a study of 44 wounds that were quiescent prior to treatment. Odor, fluid discharge, granulation, slough, and wound dimensions were monitored over a period of 5 weeks. Patients were also asked for their subjective opinion regarding discomfort during treatment.

For the purpose of the current study, it is hypothesized that wounds treated with SilverStream will show constitutional improvements in symptoms demonstrated by reduced slough, increased granulation tissue formation, reduced odor, reduced serous discharge, and decrease in wound size. Furthermore, it is hypothesized that patients will find the treatment to be soothing and without symptoms of pain.

#### METHODS:

In this review of medical records, patients with quiescent, non-progressive wounds were identified at 8 clinical centers in the United States. The collected data was provided by each individual site and was blinded to protect the anonymity of all subjects.

Because this project only involved a retrospective chart review, it was deemed to be of insignificant risk and therefore no informed consent was necessary by our local institutional review board.

The clinicians at each center were experienced in wound care management. In this study, 39 wounds were identified from a total of 38 patients. Each patient met the following inclusion and exclusion criteria (Table 1). All of the clinicians were using SilverStream as part of their standard wound care protocol. Although there was some variation in the treatment regimen from site to site, the vast majority of wounds were treated either daily or every other day. Wounds were irrigated with mild pressure using either a bulb syringe or a hypodermic syringe with a needle. Typically, the solution was left on the wound for at least 30 seconds. Most patients also applied a dressing in which gauze was slightly moistened with SilverStream and was applied directly to the wound. Debridement was usually performed about every 10 to 14 days, but some centers debrided more frequently in the initial stages. Patients' comments regarding their satisfaction with the wound product, as far as comfort, reduction in odor, reduction in exudate, and overall appearance of the wounds were also collected from the chart, when possible. Objective assessments by the clinicians were performed at each site, and included changes in wound size as well as reduction in exudate and slough and increase in wound bed vascularity. All sites routinely photograph their wounds and these photos were examined in order to document the progression of the wound once treatment began. Wounds were tracked for up to 5 weeks following initiation of treatment. Adverse events and negative changes were also reviewed.

Data collection was documented at baseline and after 3 and 5 weeks of treatment. Table 2 shows the data that was collected at each visit. Data analysis included both subjective data from the clinician and the patient and included the clinician's assessment



of the wound appearance, estimates of change in percentage of slough and granulation over the surface of the wound, and whether or not there had been a change in the amount of exudate. Changes were analyzed using chi-square analysis. Objective measures of change in wound size were also analyzed using student's t-test, with statistical significance occurring at  $p \leq 0.05$ . Other measures of success included the change in wound size with time and the percentage of wounds achieving closure in 5 weeks or less.

### RESULTS:

Data was reported on a total of 39 wounds from 38 patients seen at 8 distinct clinical sites. Three additional subjects did not have data available for the 5<sup>th</sup> week of treatment, and were therefore excluded from the study analysis. None of these excluded subjects were known to have an adverse event as the reason for their discontinuation. All patients were given an adequate supply of SilverStream wound irrigation solution to treat their wound(s) based on their individual clinicians preferred protocol. Nearly all were instructed to irrigate the wounds on a daily basis and to moisten the dressing with SilverStream prior to application. The average number of applications was 4.8 times per week (SD = 1.78).

In doing the analysis, wounds that had a surface area between 1 and 15 cm<sup>2</sup> were analyzed separately, and also, as part of the general pool of data, which contained wounds that measured between 1 and 52.2 cm<sup>2</sup>. Based on the clinical data, we found that 92% of the wounds demonstrated a measurable decrease in surface area with an average reduction of 59.08% in the group measuring from 1 to 15 cm<sup>2</sup>. The overall pooled data also demonstrated a significant reduction in wound size by 33.6% as compared to initial surface area (Figure 2). In fact, 21.5% of the wounds achieved complete closure in 5 weeks or less from the initiation of treatment. Adverse events were virtually non-

existent, with 1 patient reporting an apparent hypersensitivity of silver. About 12 % of the patients complained of pain during the irrigation process, but this was not attributed to the solution itself but rather to the mechanical pressure to the wound surface associated with irrigation. 60.6% of the patients indicated that the application of SilverStream to their wounds produced a soothing sensation.

It was hypothesized that SilverStream would help to reduce cardinal signs of infection. In this study, 10 wounds exhibited signs of mild to moderate infection, including odor, purulence, local erythema, and cellulitis, and 100% of those signs of infection were resolved after 5 weeks or less of treatment. It was also hypothesized that SilverStream would play a role in the debridement of necrotic and fibrotic tissue and help to stimulate the growth of granulation tissue. There was an average increase of 19% coverage in the surface area that was covered by granulation and an average reduction of 9.4% in the percentage of wound area that was covered with fibrous and non-viable tissue (Figure 3).

#### DISCUSSION:

The hypothesis is well supported based on the data from this pilot study. Wounds treated with SilverStream improved in many respects and most showed at least a 59% reduction in surface area during the first 5 weeks of treatment. The data strongly supports the hypothesis that signs of infection are eliminated, fibrotic tissue was reduced, and granulation tissue was produced. The combination of an antimicrobial agent, detergent, and buffer has resulted in reduction in wound discharge and odor, and has led to closure in otherwise stagnant wounds.

The strong results observed here reflect the unique combination of ingredients used. Ionic silver is present in high enough concentration to reduce bacterial loads, but

low enough to preserve the integrity of the host tissues<sup>(3, 5, 6)</sup>. This is made possible by the addition of menthol, which potentiates the effect of ionic silver<sup>(7)</sup> and helps the solution to penetrate deep beyond the surface. During treatment, the process of washing the wounds and lightly saturating the dressings with SilverStream also leads to disruption of the biofilms<sup>(4)</sup>. Mild detergent is also present and this helps to reduce debris and non-viable tissue within the wound. Agitation from irrigation and debridement and optimization of wound bed conditions resulted in the formation of granulation tissue while stimulating wound closure. Although not a goal of the study, an average reduction in 2-dimensional wound size of 33.6% was achieved in 5 weeks or less.

The use of SilverStream resulted in no significant side effects and most patients described the treatment process as soothing. Odor was eliminated and exudate was well controlled. As a result, the investigator felt that patient compliance was also likely to be improved.

Closure rate and the percentage of closure relative to time are highly dependent on the initial size of the wound. In a previous analysis, it was shown through multiple regression analysis that the initial wound size does have an impact on the change in wound size, and the closure rate, over time<sup>(8)</sup>. In the current analysis, wounds were stratified in to 2 size ranges (1-15 cm<sup>2</sup> and 1-52.2 cm<sup>2</sup>), in order to more accurately assess the outcomes with regard to % of wound closure. In the study by Sheehan et. al.,<sup>(1)</sup> the average wound size was 2.8cm<sup>2</sup>, as compared to the current study, where the average wound size was 6.07cm<sup>2</sup> in the smaller wound size cohort and 11.01cm<sup>2</sup> overall. Using Sheehan, et. al.'s benchmark of 53% decrease in wound size over the first 4 weeks of treatment, it is clear that treatment with SilverStream has stimulated the wounds to heal and will likely to result in closure in 59% or more of the wounds by week 12.

CONCLUSIONS:

This study has demonstrated that SilverStream can play a critical role in the treatment of diabetic foot ulcers and venous leg ulcers. It fills a unique niche as a solution designed to stimulate and enhance wound healing in chronic, non-progressive wounds.

The data presented here shows that wounds treated with SilverStream show an increase in granulation tissue formation, decrease in the presence of non-viable tissue, and removal of biofilms as demonstrated by reduction in slough tissue on the surface of the wounds. In fact, 92% of the wounds showed a decrease in size with an average reduction in wound size by 59.08% in wounds up to 15cm<sup>2</sup>, and 33.60% in wounds as large as 52.2cm<sup>2</sup> during the 5 weeks of observation.

Most patients found the solution soothing to use and this is attributed to the menthol component, which has a cooling and calming effect and also combats odors and helps to disrupt slough and biofilms.

100% of the wounds that began with some sign of infection achieved complete resolution by week 5 without apparent damage to the host tissue. This can be attributed to the antimicrobial agent in SilverStream, ionic silver.

Although SilverStream does help to close wounds, its greatest attribute appears to be the ability to normalize conditions within the wound bed by reducing slough, increasing granulation tissue, controlling odor, and reducing bacteria load. The investigators observed clear improvement in the overall condition of wounds treated with SilverStream and believe that it can be used as an excellent daily wound treatment or can be used to prepare the wound for more advanced biologic tissue grafts and skin substitutes.

ACKNOWLEDGEMENTS:

We would like to thank doctors from the following medical centers who contributed patients to this study:

- Dr. R. Maloney, Beverly Hospital
- Dr. T Phillips and Dr. J. Powers, Boston Medical Center
- Dr. C. Milne, Bristol Hospital
- Division of Podiatric Surgery, Cambridge Health Alliance
- Dr. W. Caputo Clara Mass Hospital
- Dr. K. Johnson-Arbor, Hartford Hospital
- Dr. B. Rosenblum, New England Sinai Hospital
- Dr. M. Rothstein, New York College of Podiatric Medicine

Submitted for Publication

REFERENCES:

1. Sheehan P, Jones P, Caselli A, Giurini JM, Veves A. Percent change in wound area of diabetic foot ulcers over a 4-week period is a robust predictor of complete healing in a 12-week prospective trial. *Diabetes Care*. 2003 Jun;26(6):1879-82.
2. Wright JB, Lam K, Burrell RE. Wound management in an era of increasing bacterial antibiotic resistance: a role for topical silver treatment. *Am J Infect Control*. 1998 Dec;26(6):572-7.
3. Jung WK, Koo HC, Kim KW, Shin S, Kim SH, Park YH. Antibacterial activity and mechanism of action of the silver ion in *Staphylococcus aureus* and *Escherichia coli*. *Appl Environ Microbiol*. 2008 Apr;74(7):2171-8. Epub 2008 Feb 1.
4. Evaluation of an Ionic Silver Solution against Dual Species In-Vitro Wound Biofilms, submitted for publication, Garth James, PhD, Center for Biofilm Engineering, Montana State University-Bozeman, 366 EPS Building, P.O. Box 173980, Bozeman, MT 59717-3980
5. Klaus T, Joerger R, Olsson E, Granqvist CG. Silver-based crystalline nanoparticles, microbially fabricated. *Proc Natl Acad Sci U S A*. 1999 Nov 23;96(24):13611-4.
6. Feng QL, Wu J, Chen GQ, Cui FZ, Kim TN, Kim JO. A mechanistic study of the antibacterial effect of silver ions on *Escherichia coli* and *Staphylococcus aureus*. *J Biomed Mater Res*. 2000 Dec 15;52(4):662-8.
7. Internal Study; EnzySurge, Ltd., 2009.
8. Landsman AS, Cook J, Cook E, Landsman AR, Garrett P, Yoon J, Kirkwood A, Desman E. A retrospective clinical study of 188 consecutive patients to examine the effectiveness of a biologically active cryopreserved human skin allograft (TheraSkin®) on the treatment of diabetic foot ulcers and venous leg ulcers. *Foot Ankle Spec*. 2011 Feb;4(1):29-41. Epub 2010 Dec 6.

**Table 1: Inclusion and Exclusion Criteria**

Inclusion Criteria	Exclusion Criteria
<ul style="list-style-type: none"> <li>• Diabetic foot ulcer or venous leg ulcer</li> <li>• Ulcers containing slough, limited granulation, odor</li> <li>• Highly exudative, slightly exudative, and dry wounds</li> <li>• Wounds showing lack of progress or worsening over a period of at least 4 weeks</li> <li>• Wagner grade 1 or 2 ulcer</li> <li>• IDDM or NIDDM</li> <li>• Age 18-70 years old</li> <li>• Able to use protective shoe gear, or non-weight bearing status</li> </ul>	<ul style="list-style-type: none"> <li>• Wounds caused by other conditions such as surgical dehiscence, pyogenic gangranosum, and chemotherapy</li> <li>• Wounds present for less than 1 month</li> <li>• Wounds showing slow progression in healing over the prior 4 weeks</li> <li>• Wounds caused by acute trauma</li> <li>• Wounds caused by burns</li> <li>• Exposed bone or osteomyelitis</li> <li>• Evidence of gangrene</li> <li>• Wounds larger then 60cm<sup>2</sup></li> </ul>

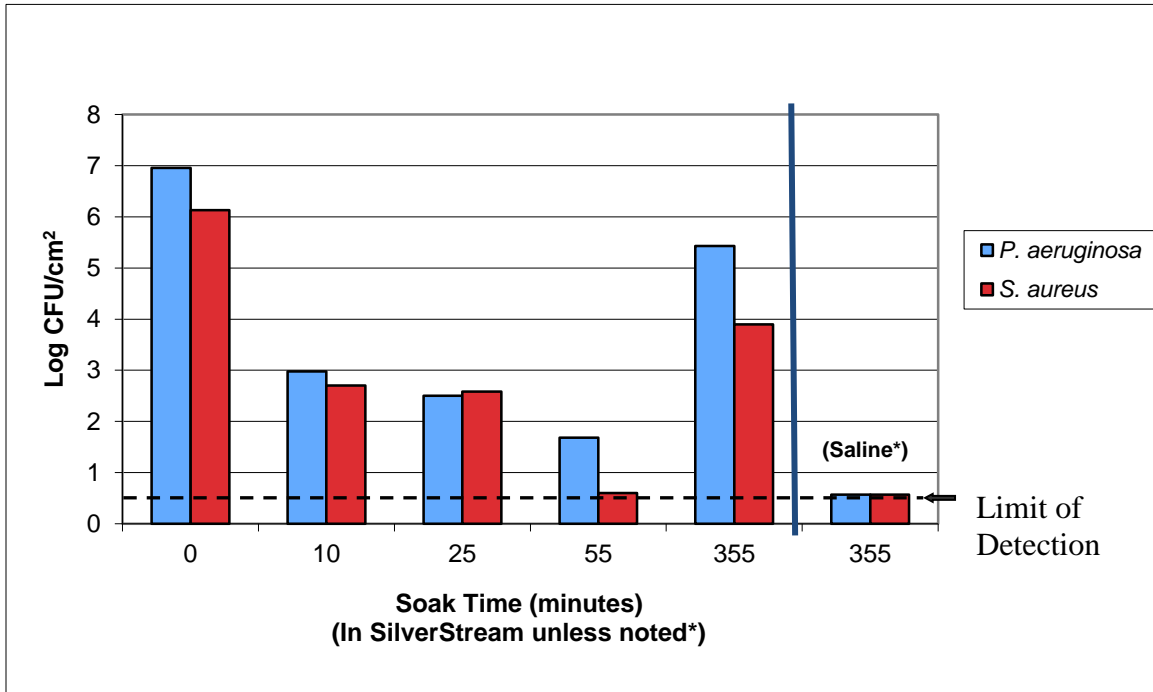
Submitted for Publication

Table 2: Data Collection

	<b>WOUNDS (n= 30)</b> <b>1-14.6 cm<sup>2</sup></b>	<b>ALL WOUNDS (n=39)</b> <b>1-52.2 cm<sup>2</sup></b>
<b>Average Initial Wound Size</b>	6.07 cm <sup>2</sup> (SD=2.13 cm <sup>2</sup> )	11.01 cm <sup>2</sup> (SD= 11.65 cm <sup>2</sup> )
<b>Average Wound Size after 3 weeks</b>	5.23 cm <sup>2</sup> (SD= 3.09 cm <sup>2</sup> )	9.28 cm <sup>2</sup> (SD= 12.02 cm <sup>2</sup> )
<b>Wound Size after 5 weeks</b>	3.14 cm <sup>2</sup> (SD=2.02 cm <sup>2</sup> )	8.26 cm <sup>2</sup> (SD= 10.92 cm <sup>2</sup> )
<b>Average % Change in wound size between baseline and 5 week visit</b>	-59.08%	-33.60% reduction in surface area
<b>Presence of cardinal signs of infection</b>	Absent in 100% of the cases following treatment for 5 weeks or less	
<b>% of granulation tissue covering the wound bed</b>	Granulation tissue coverage over the surface of the wound increased 19% on average	
<b>% of non-viable tissue on wound surface (slough, necrosis)</b>	The amount of fibrotic tissue and non-viable (slough) decreased by 9% of the wound surface area on average.	
<b>Physician perception of treatment</b>	Improved	
<b>Patient perception of treatment outcome</b>	Improved	
<b>Wound Closure</b>	21.5% of all wounds achieved 100% closure within 5 weeks of treatment	
<b>Adverse Events</b>	Hypersensitivity to Silver (3.3%) Discomfort during wound irrigation (12%)	



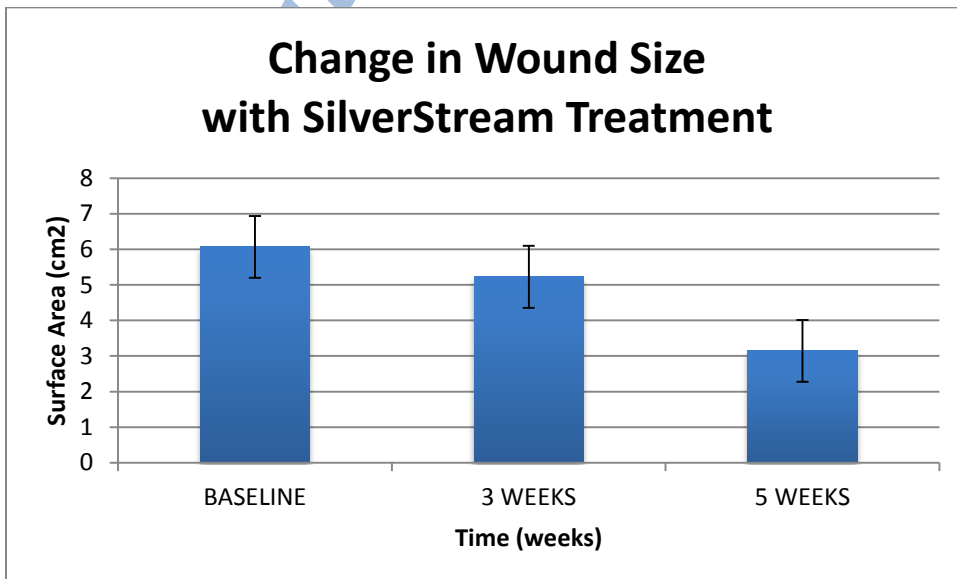
**FIGURE 1: Elimination of Biofilms with SilverStream solution for *P.aeruginosa* and *S. aureus***



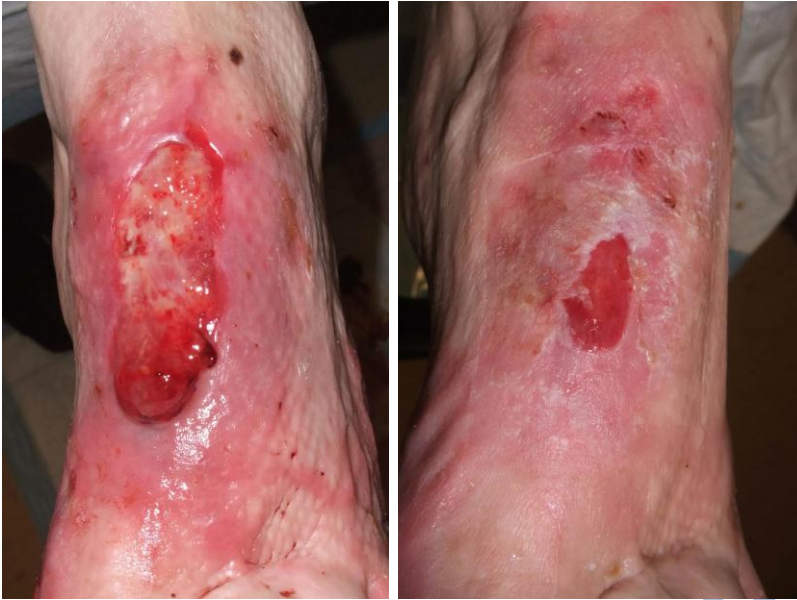Reference:

Garth James, PhD, Center for Biofilm Engineering, Montana State University-Bozeman, 366 EPS f, P.O. Box 173980, Bozeman, MT 59717-3980

**FIGURE 2: Average wound size (cm<sup>2</sup>) at Baseline, and after 3 weeks and after 5 weeks in wounds that were 1-15cm<sup>2</sup>.**



**Figure 3: Reduction in fibrotic tissue and increase in granulation tissue can be seen in this wound treated with SilverStream for 5 weeks.**



Submitted for Publication